

RESEARCH PAPER

81

BMRC Journal

Vol. 50,

No. 2,

AUGUST 2024

Clinicopathological Study of Sarcoma Involving the Oral and Maxillofacial Region

Md. Imrul Hasan^{1*}, A.F.M. Shakilur Rahman², Soroar Jahan Towhid¹, Al Hasan Md. Bayzid³,
Shyamal Kumar¹, Ismat Ara Haider¹

¹Department of Oral and Maxillofacial Surgery, Dhaka Dental College and Hospital, Mirpur-14, Dhaka,

²Department of Oral and Maxillofacial Surgery, Rajshahi Medical College Dental Unit, Rajshahi, ³Department of Casualty, Dhaka Dental College and Hospital, Dhaka

Abstract

Background: Malignant connective tissue tumors, or sarcomas, are derived from the connective tissue of the body. They fall into two categories: hard tissue sarcomas, such as osteosarcoma, Ewing's sarcoma, and chondrosarcoma, and soft tissue sarcomas, such as leiomyosarcoma and rhabdomyosarcoma. Clinicopathological research can shed light on the biological activity of oral sarcomas.

Objective: The study intends to explore clinical, pathological, and radiological aspects of sarcoma affecting the oral and maxillofacial regions in a tertiary health care center in Dhaka, Bangladesh.

Method: It was a descriptive cross sectional study carried out in the Department of Oral and Maxillofacial Surgery, Dhaka Dental College and Hospital, during the period from January 2017 to December 2018. Regardless of age or gender, 20 individuals with maxillofacial sarcoma who met the inclusion and exclusion criteria and had a histological diagnosis were enrolled.

Results: A total of 215 maxillofacial malignancies were found, of which 20 (9.3%) were sarcomas. Numerous histopathological varieties were identified, with fibrosarcoma making up the majority of cases (30%), followed by rhabdomyosarcoma (25%), osteosarcoma (15%), and Ewing's sarcoma (10%). The proportion of men to women was 1:1. Patients with sarcomas ranged in age from one year to sixty years (mean age, 22.75 ± 13.79 years). The area primarily impacted was the anterior maxilla (25%), followed by the left body of the mandible (15%), the right maxilla (10%), and the right body of the mandible (10%). The clinical manifestations of sarcoma included swelling in all patients, pain (85%), toothaches (85%), loose teeth (70%), ulcers (50%), paresthesia (50%), and restriction of mouth opening (40%). The radiological findings revealed that 30% of patients exhibited a widening of the periodontal ligament space, and 65% of patients had tooth resorption and displacement.

Conclusion: Out of 215 maxillofacial malignancies 9.3% were sarcomas, with fibrosarcoma being the most common kind. In addition to radiologically showing tooth resorption, displacement, and widening of the periodontal ligament, the majority of patients also reported pain and swelling.

Keywords: Clinicopathological, maxillofacial region, sarcoma.

Introduction:

The rare and varied class of hard tissue tumors known as sarcomas is derived from mesenchymal progenitor cells.¹ They account for fewer than 1% of all cancer cases.² These cancers can strike at any time of life, affect any part of the body, and have over 50 distinct histologic variations.³ Because the condition is

uncommon and there are many different subtypes of the lesion, studying these lesions can be quite difficult.^{3, 4}

In the oral cavity, sarcomas include less than 1% of all lesions; in the head and neck region, they represent roughly 1% of all malignancies.^{1, 5} Islam *et al.*⁶ reported that sarcomas accounted for 6.6% of oral malignancies in the Bangladeshi population. Budhy *et al.*⁷ found 4.5% sarcoma, while squamous cell carcinoma made up 70% of East Java, Indonesia. Patients with this form of tumor are associated with considerable morbidity and death rates, as well as challenges with management.⁴ The poor prognosis is

***Correspondence:** Dr. Md. Imrul Hasan, Department of Oral and Maxillofacial Surgery, Dhaka Dental College and Hospital, Mirpur-14, Dhaka

e-mail address: imrul15bds@gmail.com

ORCID ID: 0009-0008-5289-0371

directly related to the challenges of maintaining proper surgical margins, as most tumors are near vital organs. It can also lead to significant complications later on for patients having surgery.^{1, 8, 9}

Clinicopathological research can shed light on the biological activity of oral sarcomas.^{5, 10}

The study aims to analyze the prevalence, clinical presentation, histopathological types, and radiological features of oral and maxillofacial sarcomas in a tertiary healthcare center, aiming to improve early detection, accurate diagnosis, and treatment planning, ultimately improving patient outcomes.

Material and Methods

The Dhaka Dental College and Hospital's Department of Oral and Maxillofacial Surgery did the observational study from January 2017 to December 2018. On December 28, 2016, the Dhaka Dental College's ethical committee gave its approval for the current research (Ref: DDC/F5/2016/2239). Maxillofacial sarcoma patients who were histopathologically diagnosed attended the hospital, which was taken in the present study. Patients who had not given consent, previously treated or irradiated patients, and recurrent cases were excluded from this study. For population-based studies, the sample size is calculated using the Cochran formula. We estimated the prevalence of sarcoma at 6.6% and calculated using the Cochran formula that the minimum sample size required would be approximately 95 patients. We counted that only around 215 cases of maxillofacial malignancies occur at the hospital, and for a finite sample, we may need around 66 patients. The recruitment of 95 or 66 patients is not feasible; adjustments had been made based on time and resources. Regardless of age or gender, 20 individuals with maxillofacial sarcoma who met the inclusion and exclusion criteria and had a histological diagnosis were enrolled. The required data regarding the study subject was gathered through a standard data collection form.

The following variables were studied: the neoplasm's primary anatomical site, age, gender, histological diagnosis, clinical manifestations, and radiological evidence. All of the collected data underwent descriptive statistical analysis employing the SPSS program (version 22; SPSS, Inc., Chicago, IL). To describe the distribution and allocation of various sarcomas, percentage and frequency tables were employed.

Results

In this study, out of 215 maxillofacial malignancies seen within the last 2 years, 20 (9.3%) were

sarcomas. The mean age (\pm standard deviation) of the patients was 22.75 (\pm 13.79) years. The patient's age ranged from one to sixty years. The age group of 11–20 comprised the majority of patients ($n = 10$, 50%), followed by 5 patients (25%) who were over 30, and 3 patients (15%) who were in the 21–30 age group. Male and females were equal in distribution (Table I).

Table I: Analysis of the data from oral and maxillofacial sarcoma cases

Variable	Category	Total number of cases (%)
Age (years)	0-10	2 (10)
	11-20	10 (50)
	21-30	3 (15)
	>30	5 (25)
	Total cases	20 (100)
	Mean age (years) \pm SD = 22.75 \pm 13.79 Age range = 1-60 years	
Gender	Male	10 (50)
	Female	10 (50)
	Male: Female	1: 1
Site of tumours	Anterior maxilla	5 (25)
	Left body of mandible	3 (15)
	Right maxilla	2 (15)
	Right body of mandible	2 (10)
	Right posterior buccal mucosa	1 (5)
	Symphysis of mandible	1 (5)
	Left posterior buccal mucosa	1 (5)
	Left lower vestibular mucosa	1 (5)
	Right angle of mandible	1 (5)
	Hard and soft palate	1 (5)
	Right body, angle, ramus of mandible	1 (5)
	Hard palate	1 (5)
	Total	20 (100)
Histopathological diagnosis	Osteosarcoma	3 (15)
	Fibrosarcoma	6 (30)
	Rhabdomyosarcoma	5 (25)
	Chondrosarcoma	1 (5)
	Ewings sarcoma	2 (10)
	Others (Ameloblastic fibrosarcoma, leiomyosarcoma)	3 (30)
	Total	20 (100)
Clinical presentation	Swelling	20 (100)
	Pain	17 (85)
	Ulceration	10 (50)
	Paresthesia	10 (50)
	Nasal bleeding	2 (10)
	Toothache	17 (85)
	Loose tooth	14 (70)
	Limitation of mouth opening	8 (40)
Radiological findings	Sun ray appearance	3 (15)
	Widening periodontal ligament	6 (30)
	Distorted cortical bone with extra-cortical bone	4 (20)
	Tooth resorption and displacement	13 (65)
	Others	4 (20)

SD, standard deviation

Regarding histopathological diagnosis, a maximum of six (30%) patients had fibrosarcoma, followed by five (25%) with rhabdomyosarcoma, three (15%) patients had osteosarcoma, and two (10%) patients had Ewing's sarcoma (Table I). Most of the patients (n = 5, 25%) had tumors in the anterior maxilla; three (15%) had tumors in the left body of the mandible; two (10%) had tumors in the right maxilla; and two (10%) had tumors in the right body of the mandible (Table I). The distribution of the individual lesion in the oro-facial region in relation to the site was demonstrated in Table II.

All patients had swelling and pain in 85% of cases; toothache in 85%; loose teeth in 70%; ulceration in 50% of cases; paresthesia in 50%; limitation of mouth

opening in 40% of cases; and nasal bleeding in 10% of cases (Table-I). Most of the patients (n = 13, 65%) had tooth resorption and displacement; 6 (30%) patients had a widening periodontal ligament; 4 (20%) patients had distorted cortical bone with extra-cortical bone; 3 (15%) patients had sun ray appearance; and 4 (20%) patients had other radiological findings (Table I).

Fibrosarcoma was more common (n = 4, 20%) in males and rhabdomyosarcoma (n = 4, 20%) in female patients (Fig-1).

Six respondents, those who had osteosarcoma, all had complaints of swelling, pain, paresthesia, toothache, loose teeth, and limitations of mouth opening in 66.7% cases. Among six fibrosarcoma patients (Fig-2).

Table II: Distribution of the individual lesion in orofacial region relation with site (n=20)

Site of lesion	Histopathological diagnosis					
	Osteo-sarcoma	Fibro-sarcoma	Rhabdomyo-sarcoma	Chondro-sarcoma	Ewing's sarcoma	Others
Left body of mandible	0	2	1	0	0	0
Anterior maxilla	1	0	3	1	0	0
Right maxilla	0	1	1	0	1	0
Right posterior buccal mucosa	0	0	0	0	0	1
Symphysis of mandible	0	1	0	0	0	0
Right body of mandible	0	1	0	0	1	0
Left posterior buccal mucosa	0	0	0	0	0	0
Left lower vestibular mucosa	0	0	0	0	0	1
Right angle of mandible	1	0	0	0	0	0
Hard and soft palate	0	1	0	0	0	0
Right body, angle, ramus of mandible	1	0	0	0	0	0
Hard palate	0	0	0	0	0	1
Total	3(15%)	6(30%)	5(25%)	1(5%)	2(10%)	3(15%)

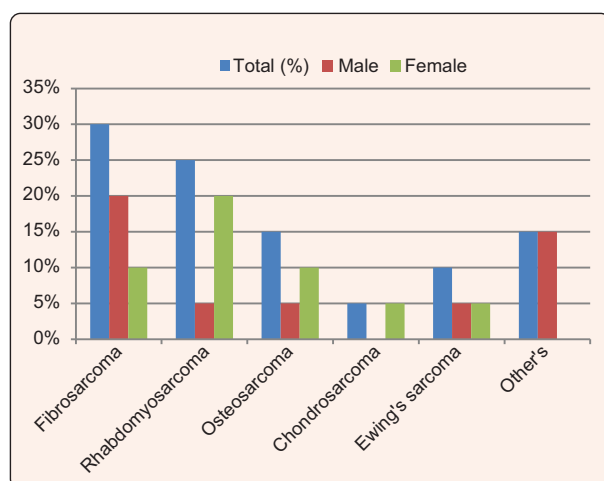


Figure 1: Histopathological diagnosis of sarcoma patient relation with sex (n=20)

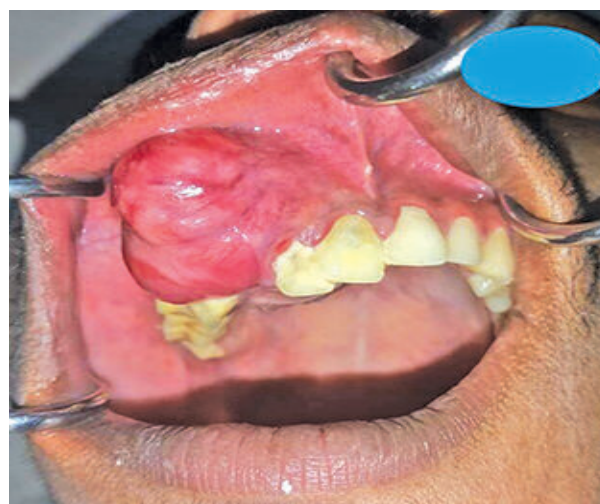

Figure 2: Intraoral image showing the right maxillary swelling of a fibrosarcoma patient

All had swelling and toothache, and 83.3% had pain. Among five rhabdomyosarcoma patients (Fig-3),

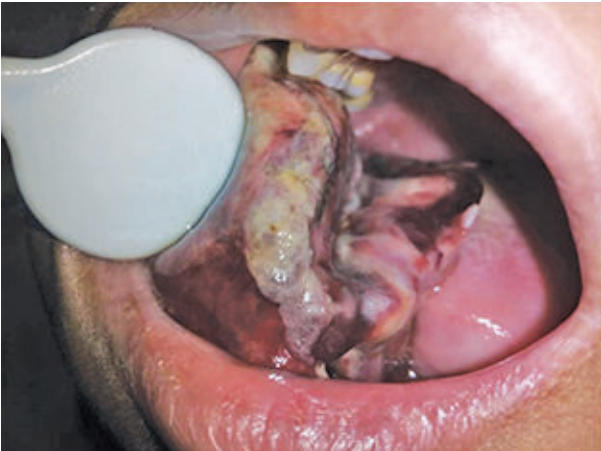

Figure 3: Intraoral image of a ulcerated swelling on posterior aspect of mandible of a rhabdomyosarcoma patient

All had swelling, pain, ulceration, and loose teeth; 40% had paresthesia, nasal bleeding, toothache, and limitation of mouth opening. Among the two patients with Ewing's sarcoma (Fig-4),

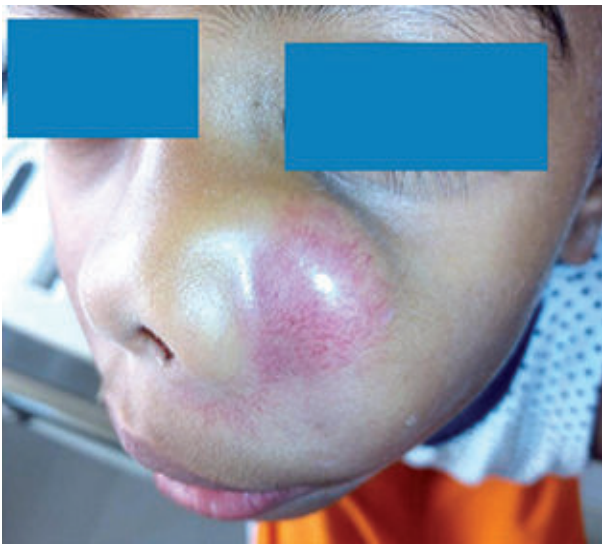

Figure 4: Extra-oral clinical photograph of a Ewing's sarcoma patient showing diffuse swelling on left maxilla.

All had swelling, pain, ulceration, paresthesia, toothache, and loose teeth. Among three other types of sarcoma, all of the patients had swelling and toothache (Table III).

Table III: Distribution of the lesion by histopathological findings and clinical feature (n=20)

Clinical features	Histopathological diagnosis					
	Osteo-sarcoma	Fibro-sarcoma	Rhabdomyo-sarcoma	Chondro-sarcoma	Ewing's sarcoma	Others
Swelling	3(100%)	6(100%)	5(100%)	1(100%)	2(100%)	3(100%)
Pain	3(100%)	5(83.3%)	5(100%)	0(0%)	2(100%)	2(66.7%)
Ulceration	0(0%)	1(16.7%)	5(100%)	0(0%)	2(100.0%)	2(66.7%)
Paresthesia	3(100%)	3(50%)	2(40%)	1(100%)	2(100.0%)	1(33.3%)
Nasal bleeding	0(0%)	0(0%)	2(40%)	0(0%)	0(0%)	0(0%)
Toothache	3(100%)	6(100%)	2(40%)	1(100%)	2(100%)	3(100%)
Loose tooth	3(100%)	3(50%)	5(100%)	1(100%)	2(100%)	2(66.7%)
Limitation of mouth opening	2(66.7%)	2(33.3%)	2(40%)	0(0%)	1(50%)	1(33.3%)
Total	3(100%)	6(100%)	5(100%)	1(100%)	2(100%)	3(100%)

Discussion

Sarcomas of the oral and maxillofacial region (SOMR) pose a great challenge because of the uncommonness of their incidence and miscellany of clinical appearance. Due to their rarity, pathologists, physicians, and researchers have studied the biological nature of these tumors in an effort to comprehend the elements that may contribute to their pathogenesis and outcome.^{3, 4} Thus, this study's goal was to review the clinicopathological characteristics of 20 SOMR from a Bangladeshi tertiary healthcare facility.

In the present study, the patients ranged in age from 1 to 60. The mean age of the patients was 22.75 ± 13.79 years. Maximum 10 (50%) patients aged within 11–20 years, followed by 5 (25.0%) patients aged above 30 years, and 3 (15%) patients aged 21–30 years. *Kumar et al.*¹¹ reported in a similar study that the tumor first appeared in individuals between the ages of 4 and 75, which is a wide range. At the time of diagnosis, 34.61% of the individuals presented were under the age of 18, and the mean patient age was 30 years. The patients in the current study did not exhibit a gender bias. In a study, it was reported that the male to female ratio was 2:1, with 67% of patients being male and 33% being female.¹²

The study revealed that 30% of patients had fibrosarcoma, followed by 25% rhabdomyosarcoma, 15% osteosarcoma, and 10% Ewing's sarcoma. The most prevalent oral and maxillofacial sarcoma in pediatric patient is rhabdomyosarcoma,¹³ while in adults, osteosarcoma is commonly found, as reported in an earlier research article.¹⁴ Rhabdomyosarcomas have been reported to be more common in Caucasians than in Black people, suggesting a hereditary component in the Caucasoid background.¹⁵ Over the course of a 15-year research, 37% of sarcomas in Ibadan, Nigeria, were osteosarcomas.¹⁶ A total of 32 instances of sarcomas affecting the oral and maxillofacial regions were studied by Yamaguchi *et al.*²; nine of these cases were osteosarcomas.

In this study among 20 patients, maximum fibrosarcoma was found in 30% of cases, which was male preponderance. Fibrosarcoma accounted for 38% of the three forms of sarcoma. This was higher than the result of this study.¹⁴ In this series, fibrosarcomas of the craniofacial area were predominantly male, in contrast to a recent report that reported a little female preponderance.¹⁷

The maxillofacial region's soft tissues are first affected by fibrosarcomas, then the maxillary sinus, various paranasal sinuses, and the nasopharynx.¹⁸ The sarcoma was found more frequently in the mandible than the maxilla in the jaws of a Dutch sample. We found the mandibular (66.7%) predominance in our study. Slootweg and Muller¹⁹ reported that out of seven individuals with fibrosarcoma, painful swelling was found in 31 people with tooth mobility, pathological fracture, trismus, and lower lip paraesthesia in one case each. Out of the six cases in our study, all presented with swelling with or without pain, ulceration, toothache, paresthesia, a loose tooth, and a limitation of mouth opening.

Rhabdomyosarcomas are the most frequent maxillofacial sarcoma in children, although they can occur at any age. The lesion tends to be most prevalent during the first ten years of life.²⁰ In India, five instances with an average age of 16 years (range: 4–33), 80% in the first and second decades, were reported.²¹ In this study, one case of rhabdomyosarcoma was involved in the oral cavity, and the patient age was 12 years. The clinical presentation was swelling, ulceration, and limitation of mouth opening.

A very aggressive tumor called Ewing's sarcoma arises from the medullary tissue of bones. It represents 4–5% of primary bone malignancies.²² Although it is uncommon, Ewing's sarcoma is the second most frequent malignant bone neoplasm in children and adolescents. Males have a higher incidence than females, and 90% of cases of Ewing's sarcoma occur in the first three decades of life. Less than 3% of cases begin in the maxillofacial region, typically affecting the lower jaw. Clinical manifestations like pain, swelling, and sensory abnormalities are generally vague and might be deceptive.²³ We had two cases of Ewing's sarcoma, one male and one female. One case involved the mandible, and the other was in the maxilla. Our Ewing's sarcoma patient's main clinical presentation was swelling and pain with ulceration, paresthesia, toothache, a loose tooth, and limitation of mouth opening.

Ameloblastic fibrosarcoma, the malignant version of ameloblastic fibroma-odontogenic tumor, is marked by benign epithelium and malignant fibrous stroma. Muller *et al.*²⁴ documented five instances of this tumor type. The patients' ages ranged in mean from 14.6 to 22 years. Park Hae Ryou *et al.*²⁵ reported a highly

malignant ameloblastic fibrosarcoma located in the right retromolar region. The patient was a 17-year-old male, and his complaint was a painful mass in this region. Clinically, the right retromolar region of the patient had an exophytic, strawberry-looking tumor. The second molar on the lower right jaw was loose. A male case of ameloblastic fibrosarcoma that was involved in the right retro-molar area presented with painless swelling and a loose tooth whose size was about 3cm in maximum dimension. The patient was treated with a partial mandibulectomy.

Osteosarcoma is more common in the mandible than the maxilla, according to the current study. While tumor involvement in soft tissues is possible, it is uncommon. Mardinger *et al.*²⁶ reported osteosarcoma found more frequently in the mandible than the maxilla.

Compared to osteosarcoma, chondrosarcoma is less prevalent. Chondrosarcoma prevalence was reported to be 12% in a published article.¹⁴ Compared to our study, this is determined to be higher (7%). Males are more likely than females to develop this lesion, a proportion of 2:1, but in our study, only one case was found out of 20 maxillofacial sarcomas. Compared to other regions of the body, the lesion more commonly affects younger individuals in the area of the oral cavity and jaws.²⁷ Our one chondrosarcoma male patient was 60 years old. The site of the lesion in our patient was the mandible, which presented with swelling, paresthesia, toothache, and a loose tooth. To determine the real anatomical site predilection for chondrosarcoma in our sample, wider data are required. The upper jaw is more commonly affected by primary chondrosarcoma than the lower jaw.²⁷

The present study showed that at the site of sarcoma, 5 (25%) patients had anterior maxilla, 3 (15%) patients had left body of mandible, 2 (10%) patients had right maxilla, and 2 (10%) patients had right body of mandible. Kumar *et al.*¹¹ noted that the locations of sarcoma were the maxilla (46%), mandible (46%), and other sites (7.6%). In this series, the clinical presentation of sarcoma patients showed that all of the patients had swelling, pain in 85% cases, toothache in 85% cases, loose teeth in 70.0% cases, ulceration in 50.0% cases, paresthesia in 50%, limitation of mouth opening in 40% cases, and nasal bleeding in 40% cases. According to clinical reports by Wanebo *et al.*²⁸, patients with SOMR typically have ambiguous symptoms at first, with most

presenting with painless swelling that goes away quickly and no other symptoms. According to Aljabab *et al.*²⁹ discomfort is typically observed in conjunction with bone sarcomas. In a series of cases, Kumar *et al.*¹¹ showed that just two patients (one each with rhabdomyosarcoma and Ewing's sarcoma) had painful swelling; additional typical exhibiting symptoms included tooth movement, pain, breach of cortical plates, and ulcers of the overlying mucosa. Cases of osteosarcoma reported by Doval *et al.*³⁰ presented swellings of the jaws, while a few had pain, tooth loosening, derangement of teeth, and ulceration. The primary manifestations included swellings, pain, toothaches, paresthesia, loose teeth, and limitations of mouth opening.

In the present study, radiological findings were tooth resorption and displacement, widening periodontal ligament space, distorted cortical bone with extra-cortical bone, and other radiological findings. It was reported that most intraosseous sarcomas as ill-defined radiolucency.³¹ A small number of malignancies with a bone origin showed periosteal bony responses. But radiographic results are not pathognomic, and therefore shouldn't be the only basis for an evaluation. Sarcomas can appear radiographically similar to certain benign tumors, such as hemangiomas.³¹

This descriptive cross sectional study in a single tertiary-care hospital has limitations such as a small sample size, limited duration, and insufficient funding for expensive investigations. To improve disease outcomes through comprehensive data collection, we need a community-based survey, appropriate sampling, and multicenter studies with cross-specialty collaboration. Future implications of this study findings included enhanced early detection and diagnosis, guiding treatment approach, improving health care policies, and a foundation for further research on a larger scale.

Conclusion:

Sarcomas comprise 9.3% of all cancers in the maxillofacial region at the Dhaka Dental College Hospital, with fibrosarcoma being the most common variety. Radiographically, the majority of patients revealed tooth resorption, displacement, and widening of the periodontal ligament space in addition to the usual symptoms of pain and swelling. Sarcomas are uncommon tumors, but because of the high mortality and morbidity, we should take early detection and proper steps to manage. In Bangladesh, poverty,

medical ignorance, and inadequate infrastructure contribute to malignant conditions. To extend the survival rate of patients and avoid reappearance, the health sector must have funds, sound knowledge about cancer, and accessible healthcare. Regional treatment facilities are also necessary.

Acknowledgement:

I must thank all my respected teachers, doctors, colleagues, and nursing personnel for their support and cooperation during this study period. I want to thank the participants in my study for their active cooperation and participation in making this study successful.

Conflict of interest: There was no conflict of interest

Funding: Self-Funded

Ethical Clearance: Dhaka Dental College Ethical Committee

Submit Date: 25 June, 2024

Final Revision Received: 28 July, 2024

Accepted: 20 July, 2024

Publication: 01 August, 2024

References

1. Alishahi B, Kargahi N, Homayouni S. Epidemiological evaluation of head and neck sarcomas in Iran (the study of 105 cases over 13 years). Iran J Canc Preven. 2015; 8: e3432. DOI:10.17795/ijcp-3432
2. Yamaguchi S, Nagasawa H, Suzuki T, Fujii E, Iwaki H, Takagi M, et al. Sarcomas of the oral and maxillofacial region: a review of 32 cases in 25 years. Clin Oral Inv. 2003; 8: 52-5. DOI:10.1007/s00784-003-0233-4
3. González-González R, Bologna-Molina R, Molina-Frechero N, Domínguez-Malagon HR. Prognostic factors and treatment strategies for adult head and neck soft tissue sarcoma. Int J Oral Max Surg. 2012; 41:569-75. DOI:10.1016/j.ijom.2012.02.002
4. Gorsky M, Epstein JB. Craniofacial osseous and chondromatous sarcomas in British Columbia—a review of 34 cases. Oral Onco. 2000; 36:27-31. DOI:10.1016/s1368-8375(99)00042-1
5. Siegel RL, Miller KD, Jemal A. Cancer statistics, 2018. CA: Canc J Clin. 2018; 68:7-30. DOI:10.3322/caac.21442
6. Islam MA, Ali MS, Hossain MM, Hasan MN, Chowdhury TG. A demographic study on oral non squamous cell malignant tumors. Update Dent Col J. 2014; 3:34-8. DOI:10.3329/updcj.v3i2.17997
7. Budhy TI, Soenarto SD, Yaacob HB, Ngeow WC. Changing incidence of oral and maxillofacial tumours in East Java, Indonesia, 1987–1992. Part 2: Malignant tumours. Br J Oral Max Surg. 2001; 39:460-4. DOI:10.1054/bjom.2001.0718
7. Chen YM, Shen QC, Gokavarapu S, Ong HS, Cao W, Ji T. Osteosarcoma of the mandible. J Craniofac Surg. 2016; 27:1929-33. DOI:10.1097/scs.0000000000002968
9. Lee RJ, Arshi A, Schwartz HC, Christensen RE. Characteristics and prognostic factors of osteosarcoma of the jaws. JAMA Otolaryn Head Neck Surg. 2015; 141:470-7. DOI:10.1001/jamaoto.2015.0340
10. Woods RH, Potter JA, Reid JL, Louise J, Bessen T, Farshid G, et al. Patterns of head and neck sarcoma in Australia. ANZ J Surg 2017; 88:901–6. DOI: 10.1111/ans.14018.
11. Kumar P, Surya V, Urs AB, Augustine J, Mohanty S, Gupta S. Sarcomas of the Oral and Maxillofacial Region: Analysis of 26 Cases with Emphasis on Diagnostic Challenges. Pathol Onco Res. 2018; 25:593-601. DOI:10.1007/s12253-018-0510-9
12. Al-Khateeb T, Bataineh AB. Rhabdomyosarcoma of the oral and maxillofacial region in Jordanians: A retrospective analysis. Oral Surg Oral Med Oral Pathol Oral Radio Endo. 2002; 93:580-85. DOI:10.1067/moe.2002.123860
13. Gilbert M. Soft tissue sarcomas of infants and children: A clinico pathologic study of 135 cases. J Pedi Surg. 1968; 3:639-40. DOI:10.1016/0022-3468(68)90210-8
14. Rafindadi AH, Ayuba GI. Two hundred and forty six tumours and tumour-like conditions of the jaw seen in Zaria, Nigeria. Ann Afr Med. 2002; 1: 72-8. Available from: <http://hdl.handle.net/1807/5015>
15. Miller RW, Dalager, NA. Fatal rhabdomyosarcoma among children in the United States, 1960–69. Cancer. 1974; 34: 1897-1900. DOI: 10.1002/1097-0142(197412)34:6%3C1897::AID-CNCR2820340607%3E3.0.CO;2-4
16. Daramola JO, Ajagbe HA, Obisesan AA, Lagundoye SB, Oluwasanmi JO. Fibrous dysplasia of the jaws in Nigerians. Oral Surg Oral Med Oral Pathol. 1976; 42:290-300. DOI:10.1016/0030-4220(76)90162-6
17. Slootweg PJ, Muller H. Malignant ameloblastoma or ameloblastic carcinoma. Oral Surg Oral Med Oral Pathol. 1984; 57:168–76. DOI: 10.1016/0030-4220(84)90207-x
18. Batsakis JG, Sneige N. Parapharyngeal and retropharyngeal space diseases. Ann Oto Rhino Laryngo. 1989; 98: 320–1. DOI:10.1177/000348948909800416
19. Slootweg PJ, Müller H. Fibrosarcoma of the jaws. J Maxillofac Surg. 1984; 2: 157-62. DOI:10.1016/s0301-0503(84)80237-4
20. Soule EH, Mahour GH, Mills SD, Lynn HB. Soft-tissue sarcomas of infants and children: a clinicopathologic study

- of 135 cases. Mayo Clin Proceed. 1968; 43: 313-26.
PMID: 4297483
21. Pandey M, Chandramohan K, Thomas G, Mathew A, Sebastian P, Somanathan T, *et al*. Soft tissue sarcoma of the head and neck region in adults. Int J Oral Maxillofac Surg. 2003; 32(1): 43-8.
DOI: 10.1054/ijom.2001.0218
 22. Hardy P, Gibbs AR. Ewing's sarcoma of mandible. Br J Oral Maxillofac Surg. 1984; 22: 287-94.
DOI: 10.1016/0266-4356(84)90085-8
 23. Herzog CE. Overview of Sarcomas in the Adolescent and Young Adult Population. Pediatr Hematol Oncol J. 2005; 27(4):215-8.
DOI:10.1097/01.mph.0000161762.53175.e4
 24. Muller S, Parker DC, Kapadia SB, Budnick SD, Barnes EL. Ameloblastic fibrosarcoma of the jaws: a clinicopathologic and DNA analysis of five cases and review of the literature with discussion of its relationship to ameloblastic fibroma. Oral Surg Oral Med Oral Pathol Oral Radio Endo. 1995; 79 : 469-77.
DOI: 10.1016/s1079-2104(05)80130-1
 25. Park HR, Shin KB, Sol MY, Suh KS, Lee SK. A highly malignant ameloblastic fibrosarcoma. Report of a case. Oral Surg Oral Med Oral Pathol Oral Radio Endo. 1995; 79: 478-81.
DOI: 10.1016/s1079-2104(05)80131-3
 26. Mardinger O, Givol N, Talmi YP, Taicher S. Osteosarcoma of the jaw: the Chaim Sheba Medical Center experience. Oral Surg Oral Med Oral Pathol Oral Radio Endo. 2001; 91: 445-51.
DOI: 10.1067/moe.2001.112330
 27. Adekeye EO, Chau KK, Edwards MB, Williams HK. Osteosarcoma of the jaws — a series from Kaduna, Nigeria. Int J Oral Maxillofac Surg. 1987; 16:205-213.
DOI:10.1016/s0901-5027(87)80132-7
 28. Wanebo HJ, Koness RJ, Macfarlane JK, Eilber FR, Byers RM, Elias EG, *et al*. Head and Neck Sarcoma: Report of the Head and Neck Sarcoma Registry. Head Neck. 1992; 14:1-7. DOI:10.1002/hed.2880140102
 29. Aljabab AS, Nason RW, Kazi R, Pathak KA. Head and neck soft tissue sarcoma. Ind J Surg Oncol. 2011; 2:286-290.
DOI:10.1007/s13193-012-0127-5
 30. Doval DC, Kumar RV, Kannan V, Sabitha KS, Misra S, Kumar, MV, *et al*. Osteosarcoma of the jaw bones. Br J Oral Maxillofac Surg. 1997; 35:357-62.
DOI: 10.1016/s0266-4356(97)90410-1
 31. Wu JS, Hochman MG. Soft-tissue tumors and tumor like lesions: a systematic imaging approach. Radio. 2009; 253:297-316.
DOI:10.1148/radiol.253208119