

RESEARCH PAPER

Topographic and Histological Distribution of Carcinoma Pharynx and Larynx: Fiber Optic Laryngoscopic (FOL) Study of 700 Cases

Mohammad Shah Kamal^{1*}, Rubina Farzana², Md. Hafiz Ehsanul Hoque³, Md. Guljar Hossain⁴

¹Department of Otolaryngology and Head-Neck surgery, MAG Osmani Medical College, Sylhet, Bangladesh,

²Department of Paediatrics, Upazila Health Complex, Bahubal, Habiganj, ³Department of Community Medicine, MAG Osmani Medical College, Sylhet, Bangladesh, ⁴Department of Medicine, MAG Osmani Medical College, Sylhet, Bangladesh.

Abstract

Background: In Bangladesh, in 2020 estimated number of new cancer cases were 156775 and number of deaths were 108990. Carcinoma pharynx and larynx in 2020 were 7.86% and 3.4% of total new cancer cases, 5.71% and 3% of total cancer deaths. Fiber optic laryngoscopy (FOL) has been established as a valuable diagnostic tool and its accuracy is 80.65%.

Objectives: The primary objective of this study was to see the topographic and histological distribution of pharyngeal and laryngeal cancers and secondary objective was to assess the role of Flexible Endoscopic Biopsy (FEB) in the diagnosis of cancers.

Methods: This descriptive cross-sectional study was done from March 2021 to October 2022 at Mount Adora Hospital, Akhalia, Sylhet, Bangladesh. All suspected pharyngeal and laryngeal cancer patients attending in this hospital for FOL and FEB were included in this study in a convenient sampling method. Benign, recurrence and residual cases were excluded from this study.

Results: Total 700 patients of suspected pharyngeal and laryngeal cancer underwent FOL. FEB was taken from 92.6% cases. Histopathological examination of biopsy specimens revealed malignancy in 98.3% cases. Sensitivity of FEB was 98.3%. FOL and FEB were 91% successful in acquiring a definite diagnosis. Nasopharyngeal cancer affected the younger age group (mean age 39.6 year, SD=17.5). Pharyngeal cancer was more common (62.9%) than laryngeal cancer (37.1%). Hypopharynx (63.2%) was the most common site for pharyngeal cancers. In laryngeal cancer, supraglottic was more common (60%). In hypopharyngeal cancer, pyriform fossa was the most common site (87%). Squamous cell carcinoma (99.2%) was the most common histological diagnosis.

Conclusion: Pharynx was more frequent site than larynx for cancers. Supraglottic region was the most common site for laryngeal and pyriform sinus was the most common site for hypopharyngeal cancers. Nasopharyngeal cancer affected the younger age group. Common histological diagnosis was squamous cell carcinoma. Flexible Endoscopic Biopsy (FEB) was highly sensitive.

Key words: Laryngeal cancer, Hypopharyngeal cancer, Laryngoscopy, Squamous cell carcinoma.

Introduction

Cancer is the second leading cause of death globally, accounting for an estimated 10 million deaths, or one in six deaths, in 2020.¹ In Bangladesh, in 2020 estimated number of new cancer cases were 156775 and number of deaths were 108990. Carcinoma

pharynx and larynx in 2020 were 7.86% and 3.4% of total new cancer cases, 5.71% and 3% of total cancer deaths.²

In the pharynx, oropharynx is the most frequent site of primary cancer followed by hypopharynx and nasopharynx.³ In the larynx, glottic region is by far the most common site for primary malignant tumours followed by supraglottic and subglottic region.⁴ In hypopharyngeal cancers, the most common site is the pyriform sinus followed by post-cricoid region and posterior pharyngeal wall.⁵ In Bangladesh, unlike the western world, supraglottic region is the most

***Correspondence:** Mohammad Shah Kamal, Department of Otolaryngology and Head-Neck Surgery, MAG Osmani Medical College, Sylhet, Bangladesh.

Email: dr.shahkamal@gmail.com

ORCID: 0000-0003-3881-4619

common site for primary laryngeal cancers followed by glottic and subglottic region.⁵⁻⁷

Fiber Optic Laryngoscopy (FOL) has been established as a valuable diagnostic tool and is feasible at a very early stage and in critically ill patients, it is noninvasive and frequently repeatable.⁸ FOL provides a clear vision of most of the structures of pharynx and larynx including the hidden area of larynx.⁹ An additional advantage of FOL is the possibility of recording images, enabling more detailed reporting and comparison of images during follow-up.¹⁰ Diagnostic accuracy of FOL is 80.65%.¹¹ Biopsy is essential for the histological diagnosis of cancer. Traditionally, biopsy of pharyngeal and laryngeal lesion is performed by rigid direct laryngoscopy (DL) under general anaesthesia. FOL enables the clinicians to perform Flexible Endoscopic Biopsy (FEB) under topical anaesthesia in outpatient department (OPD) setting. FEB is safe, well tolerated, cost-effective, easy to perform and 92.5-95.8% successful in acquiring a definite histological diagnosis.^{5,12,13} The primary objective of this study was to see the topographic and histological distribution of pharyngeal and laryngeal cancers and secondary objective was to assess the role of Flexible Endoscopic Biopsy (FEB) in the diagnosis of cancers. This study will help otolaryngologists in early diagnosis of pharyngeal and laryngeal cancers and to obviate the need of rigid direct laryngoscopic biopsy under general anaesthesia.

Materials and Methods

This descriptive cross-sectional study was performed from March 2021 to October 2022 at Mount Adora Hospital, Akhaila, Sylhet, Bangladesh. Sylhet city is the catchment area for the patients of four districts of Sylhet division- Sylhet, Moulvibazar, Habiganj, Sunamganj. Suspected pharyngeal and laryngeal cancer patients were referred to this hospital by the otolaryngologists practicing in Sylhet division for FOL and FEB. All suspected patients attending this hospital for FOL and FEB were included in this study in a convenient sampling method. Cancers of tonsil and posterior pharyngeal wall of oropharynx were not included in this study because biopsies of these sites are taken directly using headlight and tongue depressor. Benign, recurrence and residual cases were excluded from this study.

For cleaning of the endoscopes, we used soap water first, then 2.45% w/v glutaraldehyde for manual disinfection, 10 minutes' immersion before the session

and between patients. Adequate personal protective equipment was ensured before every procedure. N95 mask, gown and gloves were used by consultant and endoscopy assistant. KM95 masks, gloves and surgical gowns were ensured for the supporting stuffs.

Following equipment were used, CV-170 videoscope processor, ENF-VT3 Rhino-laryngovideoscope with 4.8 mm distal end diameter and 2 mm inner diameter instrument channel, GIF-Q150 Gastrointestinal videoscope with 9.2 mm distal end diameter and 2.8 mm inner diameter instrument channel, FB-241 K.A biopsy forceps with 1.8mm diameter, FB-240 K.A biopsy forceps with 2.8mm diameter (Olympus Medical Systems Corp, Japan).

Transnasal fiberoptic laryngoscopy (FOL) was performed in OPD by the first author. The nasal cavity was packed with adrenaline plus lidocaine hydrochloride (5mcg+10mg/ml) soaked ribbon gauze 10-20 minutes before procedure. The pharynx was sprayed with 10% lidocaine hydrochloride spray transorally 10 minutes and immediately before the procedure. Lidocaine hydrochloride was administered through the working channel into the lumen of the larynx.

Flexible Endoscopic Biopsies (FEB) were obtained from all suspected lesions except in patients with severely compromised airway, non-cooperative patients and patients who could not tolerate the procedure due to excessive cough or pharyngeal reflex. Biopsy from nasopharyngeal, glottic, subglottic and few supraglottic growths were taken transnasally by Rhino-laryngovideoscope and biopsy forceps with 1.8mm diameter. Biopsy from base of the tongue, hypopharynx, and most of the supraglottic growths were taken perorally by gastrointestinal videoscope and biopsy forceps with 2.8mm diameter. An average of three biopsies were taken from each suspected lesion. The tissues were collected in a designated pathology plastic cup containing 10% formalin and were sent for histopathological examination in the same center. In case of inconsistency with the clinical findings, FEB was repeated or biopsy under general anaesthesia was advised. All patients tolerated the procedure well. There were no complications related to FEB except minor bleeding which was alleviated by gargling with cold water.

Data were analyzed by Statistical Package for Social Sciences [SPSS]. Qualitative data were expressed by frequency and percentage, whereas quantitative

data were expressed by mean, median, mode and standard deviation.

Results

Total 700 patients of suspected pharyngeal and laryngeal cancer underwent Transnasal Fiber Optic Laryngoscopy (FOL). Flexible Endoscopic Biopsy (FEB) was taken from 648(92.6%) cases. Histopathological examination of the biopsy specimen revealed malignancy in 637(98.3%) cases [Figure-1].

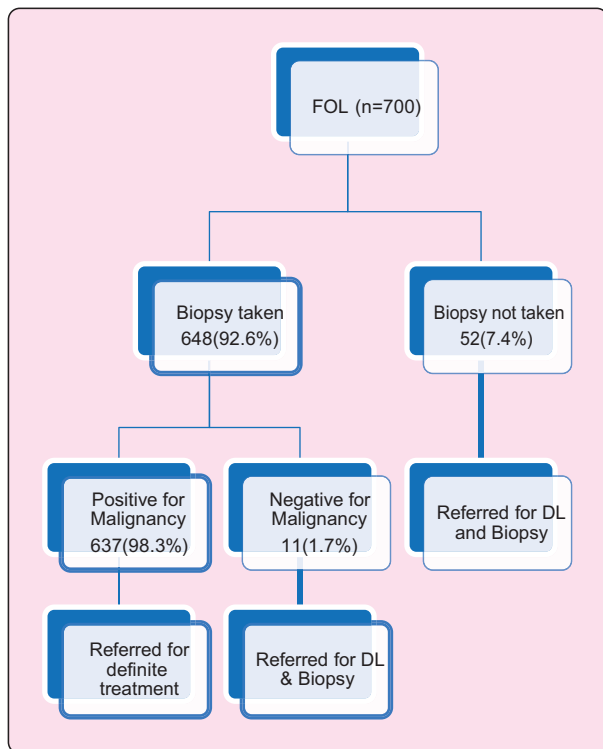


Figure 1: Result of FOL and FEB

So, by using FOL and FEB definite diagnosis was confirmed in 637(91%) cases. Sensitivity of FEB was 98.3%. These 637 patients were referred for definitive treatment (radiotherapy, combined radiotherapy and chemotherapy, and /or surgery). Remaining 63 patients were referred for DL and biopsy under general anaesthesia and their data were excluded from further statistical analysis.

Confirmed diagnosis was done in 637 patients. The age of the patients ranged from 15 to 100 years with a mean age of 58.5 year (SD=13.3). Commonest age group was 60-69 (30.1%) [Figure-2].

Majority of the patients were male. Male, Female ratio was 5.9:1. Patients with nasopharyngeal

carcinoma presented in much younger age compared to other types (p-value <0.001) [Table-I] and was relatively common in female (male, female ratio 2.4).

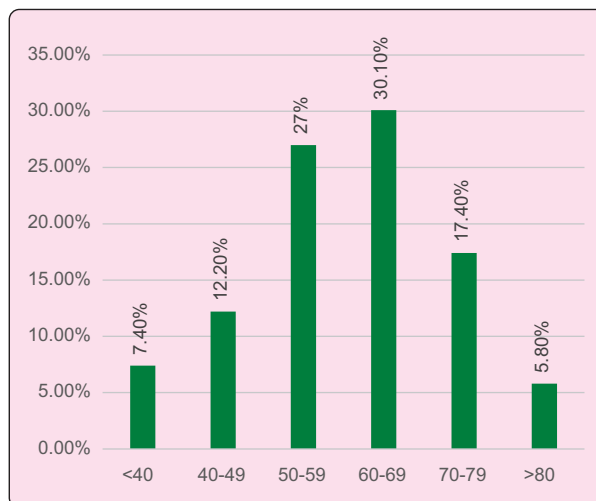


Figure 2: Age distribution of the patients(n=637)

Table I: Bivariate analysis of age of the patient with site of cancer (n=637)

Site of cancer	Mean age±SD	F-value	p-value
Nasopharynx	39.59±17.49	13.04	<0.001
Larynx	59.77±13.88		
Hypopharynx	59±12.40		
Base of the tongue	59.17±11.20		

In twelve patients' cancer was extensive and involved multiple sites, so exact origin could not be confirmed (1.88%). Synchronous second primary cancer was found in five patients (0.71%). So, a total of 620 cancer patients were taken for topographic and histological distribution. Pharyngeal cancers were 62.9% and laryngeal cancers were 37.1%. Among pharyngeal cancers, hypopharyngeal (63.2%) was most common followed by tongue base (31.9%) and nasopharyngeal cancer (4.9%). In laryngeal cancer, supraglottic was the most common site (60%) followed by glottic (36.1%) and subglottic (3.9%). In hypopharyngeal cancer, pyriform fossa was the most common site (87%) followed by posterior pharyngeal wall (7.3%), post cricoid (3.6%) and lateral pharyngeal wall (2%).

Table II: Topographical distribution of cancers (n=620)

Site	Subsite	Number (%)
Pharyngeal cancer 390 (62.9%)	Nasopharyngeal	19(4.9%)
	Tongue base	124(31.9%)
	Hypopharyngeal	247 (63.2%)
	Pyriform sinus	215 (87%)
	Right	125(58.1%)
	Left	90(41.9%)
	Posterior pharyngeal wall	18(7.3%)
	Post-cricoid	9(3.6%)
	Lateral pharyngeal wall	5 (2%)
	Laryngeal cancer 230 (37.1%)	Supraglottic
Right		56(40.6%)
Left		35(25.4%)
Epiglottic		47(34%)
Glottic		83(36.1%)
Right		32(38.6%)
Left		39(47%)
Bilateral		7(8.4%)
Transglottic		5(6%)
Subglottic		9(3.9%)

Squamous cell carcinoma (99.2%) was the most common histological diagnosis [Figure-3].

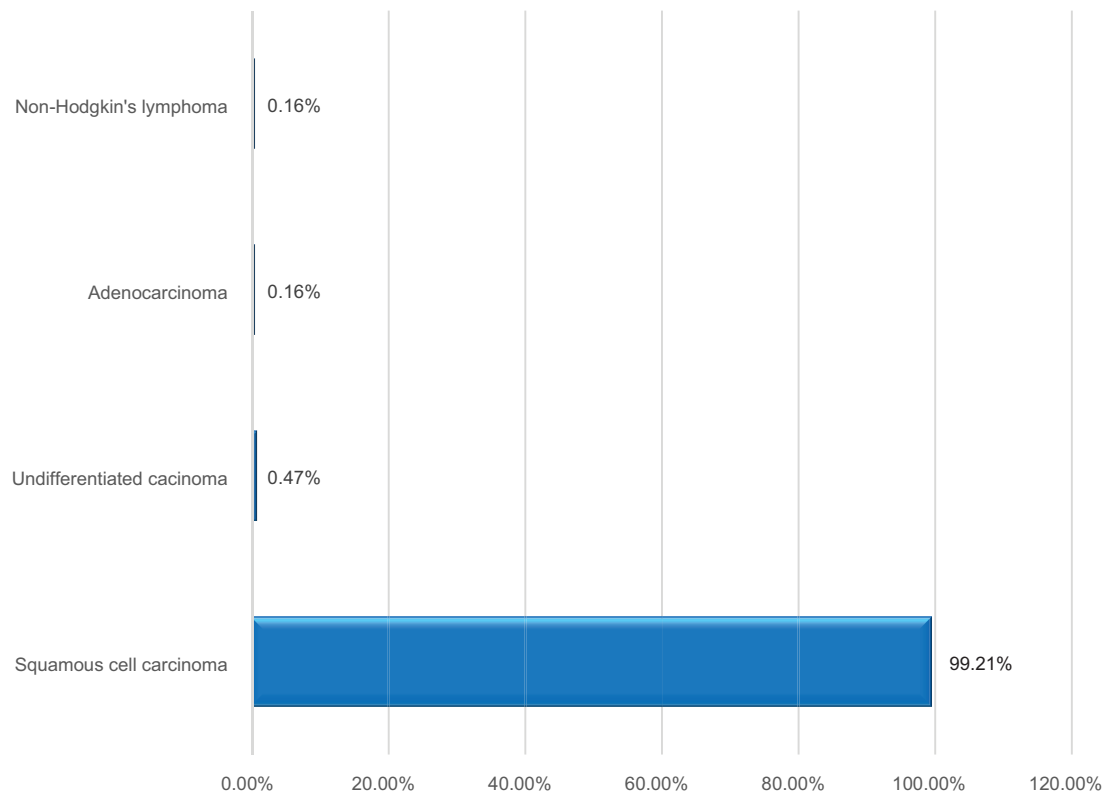


Figure 3: Histological distribution of cancers (n=620)

Discussion

Out of 700 patients, Flexible Endoscopic Biopsy (FEB) was obtained from 92.6% cases. FEB was not taken in 7.4% of patients who had severely compromised airway or could not tolerate the procedure due to excessive cough or pharyngeal reflex. This is similar with the other researchers who obtained biopsies such as Wellenstein DJ et al 97.5%,¹⁰ Cohen JT et al 94.1%,¹⁴ Cohen JT and Benyamini L 94%.¹⁵

In the current study, diagnostic sensitivity of FEB for malignancy was 98.3%. This finding is not consistent with other researchers who found low sensitivity such as Cohen JT et al (69.2%),¹⁴ Cohen JT and Benyamini L (70.6%),¹⁵ Uys HK et al (77.1%)¹⁶ and Richards AL et al (60%).¹⁷ This high sensitivity may be due to use of peroral gastrointestinal videoscope and large biopsy forceps with 2.8mm diameter and taking at least three representative biopsies from each tumour. FOL was 91% successful in acquiring a definite diagnosis which is similar to a study done in Netherlands (92.5%).¹²

In our study, the mean age of the patients was 58.5 years (SD=13.3), commonest age group was 60-69 (30.1%). Majority of the patients were male. Male, Female ratio was 5.9:1. Jyoti D et al¹⁸, Chauhan et al¹⁹ respectively found mean age 57.9 and 58.85, commonest age group 61-70(25%) and 51-60(30.8%). Male, female ratio was similar with Kamal MS et al⁵ (4.8:1) and Stoyanov GS et al²⁰ (3.24:1) but not similar with Jyoti D et al (9:1).¹⁸ In the current study Patients with nasopharyngeal cancer presented in much younger age compared to other types and was relatively common in female (male, female ratio 2.4). In Indonesia, nasopharyngeal cancer appeared to affect patients at a relatively young age (peak incidence 30-50 years of age) without a bimodal age distribution and male to female ratio of 2.4.²¹

In this study, pharyngeal cancers were more common (62.9%) than laryngeal cancers (37.1%). This finding is consistent with the estimation of International Agency for Research on Cancer (7.86% versus 3.4% of total new cancer cases).² Stoyanov GS et al²⁰ studied 619 patients of head and neck cancer and found carcinoma oral cavity- 29.08%, larynx -30.37%, pharynx -20.03%, salivary gland and others -20.52%.

Among pharyngeal cancers, hypopharyngeal (63.2%) was most common followed by tongue base (31.9%) and nasopharyngeal cancer (4.9%). Ellington TD et al studied 44419 patients of carcinoma oral cavity and

pharynx diagnosed in 2016 in USA and found that carcinoma oral cavity was 53% and pharynx 47%. Among pharyngeal carcinoma, tonsil and oropharynx was 47.3%, base of the tongue (35.3%), hypopharynx (9.6%) and nasopharynx (7.8%).²²

In laryngeal cancers, supraglottic was most common (60%) followed by glottic (36.1%) and subglottic (3.9%). Similar findings were observed by Jyoti D et al¹⁸ (supraglottic -71.79%, glottic -23.08%, subglottic- 5.13%) and Chauhan JPS et al¹⁹ (supraglottic- 69.23%, glottic -27.69%, subglottic-3.07%). Many researchers found glottis as the most common site such as Adeel M et al²³ (supraglottic -10.9%, glottic- 87.8%, subglottic-1.4%), Markou K et al²⁴ (supraglottic-32.8%, glottic-62.2%, subglottic- 1.1%, transglottic - 5.9%), Boci B and Cuko A²⁵ (supraglottic -36.4%, glottic- 49.5%, subglottic- 1.6%, transglottic -5.6%). Markou K et al studied the relation between the location of cancer and consumption of alcohol and found that the incidence of supraglottic carcinoma showed a gradual increase in proportion to the amount of alcohol consumption. The frequency of supraglottic carcinoma in non-alcoholic was 35% and heavy drinkers was 50%.²⁴

In hypopharyngeal cancers, pyriform fossa was the most common site (87%) followed by posterior pharyngeal wall (7.3%), post cricoid (3.6%) and lateral pharyngeal wall (2%). This result is consistent with Islam MN et al²⁶ who found 83.3% in pyriform fossa, 12.7% in posterior pharyngeal wall, 4% in post cricoid region and Francis DA and Menon DP²⁷ who reported 80% in pyriform fossa, 10% in posterior pharyngeal wall, 10% in post cricoid region.

Squamous cell carcinoma (99.2%) was the most common histopathological diagnosis. Other histopathological types were non-Hodgkin's lymphoma (0.16%), adenocarcinoma (0.16%) and undifferentiated carcinoma (0.47%). Many researchers reported squamous cell carcinoma in 100% of cases.^{5,18,26} But Fasunla AJ et al²⁸ found squamous cell carcinoma in 96.9%, other histopathological types were synovial sarcoma, chondrosarcoma, adenoid cystic carcinoma. Jakobsen KK et al²⁹ reported squamous cell carcinoma 90.3%, adenocarcinoma 3.6%, and other rare histology 6.1%.

Limitations

There is no direct comparison of FEB and direct laryngoscopic biopsy. We also excluded patients with

advanced laryngeal carcinoma with compromised airway to avoid the need for emergency tracheostomy.

Conclusion

Pharyngeal cancer was more common than laryngeal cancer. Among pharyngeal cancers, hypopharynx was the most common site. In laryngeal cancer, supraglottic was more common. In hypopharyngeal cancer, pyriform fossa was the commonest site. Most of the patients had squamous cell carcinoma. Nasopharyngeal cancer affects younger age group. Flexible Endoscopic Biopsy (FEB) was highly sensitive.

Acknowledgement

The authors express sincere gratitude to-

1. Prof. Dr. Amjad Hossain Khan, Professor and Head, Department of pathology, Sylhet MAG Osmani Medical College (Rtd.) for doing histopathological examination of all the samples.
2. Prof. Dr. Syed Alamgir Safwath, Professor and Head, Department of Gastroenterology, Jalalabad Ragib Rabeya Medical college and Hospital, Sylhet for providing all logistics and technical supports.

Conflict of Interest: There was no conflict of interest.

Funding: There was no funding source for this study.

Ethical approval: Mount Adora Hospital, Akhalia, Sylhet, Bangladesh.

Submitted: 05 December, 2022

Final revision received: 17 January, 2023

Accepted: 25 January, 2023

Published: 01 April, 2023

References

1. World Health Organization. Cancer [Internet]. Geneva: World Health Organization; 2022: Feb 3. Available from: <https://www.who.int/news-room/fact-sheets/detail/cancer>
2. International Agency for Research on Cancer. Bangladesh [Internet]. Global Cancer Observatory; 2021 March. Available from: <https://gco.iarc.fr/today/data/factsheets/populations/50-bangladesh-fact-sheets.pdf>
3. Vasicek SM, Ponderfer P, Holzmeister C, Graupp M, Weiland T, Wolf A. et al. Head and neck cancer in Styria. Wien Klin Wochenschr 2020;132: 444–51. DOI: 10.1007/s00508-019-01591-y.
4. Shah JP, Patel SG, Singh B, Wong RJ. Jatin Shah's Head and Neck Surgery and Oncology. Fifth edition. New York. Elsevier 2020.P.365-66. ISBN:978-0-323-41518-7.
5. Kamal MS, Farzana R, Ehsanul Hoque MH, Hossain MG. Distribution of Laryngopharyngeal Malignancy in the North-East Part of Bangladesh: Fiberoptic Laryngoscopic (FOL) Study of 300 Cases. J. Bangladesh Coll. Phys 2022; 40:99-104. DOI: 10.3329/jbcps.v40i2.58690
6. Selim MS, Islam MM, Rahim MM, Zafar MH, Asad MK, Rahman MM. Topographical Distribution of Carcinoma Larynx. Bangladesh J otolaryngol 2020; 24:56-61. DOI: 10.3329/bjo.v24i1.45342.
7. Uddin MN, Humayun AMP, Islam MB, Rahman MM. Clinicopathological study of carcinoma larynx. Bangladesh J otolaryngol 2020; 26:37-40. DOI:10.3329/bjo.v26i1.47951
8. Miteab RT. Accuracy of Fiberoptic Nasopharyngoscopy in the Diagnosis of Pharyngolaryngeal diseases. Iraqi Postgraduate Medical Journal 2015; 14:192-96.
9. Vibhuti. Role of Flexible Fiber Optic Laryngoscopy in Pharyngeal and Laryngeal Diseases. Int J Recent Sci Res 2019; 10: 36354-57. DOI: 10.24327/ijrsr.2019.1012.4906
10. Wellenstein DJ, Witt JK, Schutte HW, Honings J, Hoogen FJA, Marres HAM et al. Safety of flexible endoscopic biopsy of pharynx and larynx under topical anaesthesia. Eur Arch Otorhinolaryngol 2017; 274: 3471-76. DOI: 10.1007/s00405-017-4647-z
11. Khan RZ, Iqbal A, Saqulain G. Diagnostic Accuracy of Fiber Optic Laryngoscopy. J Islamabad Med Dental Coll. 2021; 10: 101-04. Doi: 10.35787/jimdc.v10i2.426
12. Schutte HW, Takes RP, Slootweg PJ, Arts MJPA, Honings J, Hoogen FJA et al. Digital Video Laryngoscopy and Flexible Endoscopic Biopsies as an Alternative Diagnostic Workup in Laryngopharyngeal Cancer: A Prospective Clinical Study. Ann Otol Rhinol Laryngol 2018;127:770-76. DOI: 10.1177/0003489418793987.
13. Lakshminarasimman P, Pai PS, Mehta S, Patil P. Is Direct Laryngoscopy Obsolete? "Trans Nasal Oesophagoscopy" the Complete Endoscopic Solution in Head Neck Practice. Indian J Otolaryngol Head Neck Surg 2021;73:310-14. DOI: 10.1007/s12070-021-02368-4.
14. Cohen JT, Safadi A, Fliss DM, Gil Z, Horowitz G. Reliability of a transnasal flexible fiberoptic in-office laryngeal biopsy. JAMA Otolaryngol Head Neck Surg. 2013; 139:341-45. DOI: 10.1001/jamaoto.2013.38.
15. Cohen JT, Benyamini L. Transnasal Flexible Fiberoptic in-office Laryngeal Biopsies-Our Experience with 117 Patients with Suspicious Lesions. Rambam Maimonides Med J. 2014;28;5: e0011. DOI: 10.5041/RMMJ.10145.
16. Uys HK, Pelsler A, Attwood R, Adam S, Afrogheh A, Hille I et al. Diagnosis and staging of laryngopharyngeal tumours

- with flexible endoscopy: A prospective study. *S. Afr. j. oncol* 2019;3: 56.
DOI: 10.4102/sajo.v3i0.56.
17. Richards AL, Sugumaran M, Aviv JE, Woo P, Altman KW. The utility of office-based biopsy for laryngopharyngeal lesions: comparison with surgical evaluation. *Laryngoscope* 2015; 125:909-12
DOI: 10.1002/lary.25005.
 18. Jyoti D, Arti, Kunzes, Jamwal PS. Clinical profile of the patients presenting with laryngeal and hypopharyngeal carcinoma: an institution based retrospective study. *Int J Otolaryngol Head Neck Surg* 2019;5:1161-66.
DOI: 10.18203/issn.2454-5929.ijohns20193120
 19. Chauhan JPS, Bharti B, Bhadouriya SS, Kumar A, Narain P, Singh J. Laryngeal cancer: a clinicopathological study of 65 cases. *Int J Otolaryngol Head Neck Surg* 2019; 4:163-68.
DOI: 10.18203/issn.2454-5929.ijohns20175619
 20. Stoyanova GS, Kitanova M, Dzhenkov DL, Ghenev P, Sapundzhiev N. Demographics of Head and Neck Cancer Patients: A Single Institution Experience. *Cureus* 2017;9:e1418.
DOI: 10.7759/cureus.1418.
 21. Adham M, Kurniawan AN, Muhtadi AI, Roezin A, Hermani B, Gondhowiardjo S, Tan IB, Middeldorp JM. Nasopharyngeal carcinoma in Indonesia: epidemiology, incidence, signs, and symptoms at presentation. *Chin J Cancer*. 2012; 31:185-96.
DOI: 10.5732/cjc.011.10328.
 22. Ellington TD, Henley SJ, Senkomago V, et al. Trends in Incidence of Cancers of the Oral Cavity and Pharynx — United States 2007–2016. *MMWR Morb Mortal Wkly Rep* 2020; 69:433–38.
DOI: 10.15585/mmwr.mm6915a1
 23. Adeel M, Faisal M, Rashid A, Usmam S, Khaleeq U, Abbas T et al. An Overview of Laryngeal Cancer Treatment at a Tertiary Care Oncological Center in a Developing Country. *Cureus* 2018; 1; 10: e2730.
DOI: 10.7759/cureus.2730.
 24. Markou K, Christoforidou A, Karasmanis I, Tsiropoulos G, Triaridis S, Constantinidis I et al. Laryngeal cancer: epidemiological data from Northern Greece and review of literature. *Hippokratia* 2013; 17:313-18.
PMID: 25031508
 25. Boci B, Cuko A. Laryngeal cancer, risk factors, symptoms and treatment. *Arch Otolaryngol Rhinol* 2020; 6: 021-28.
DOI: 10.17352/2455-1759.000116
 26. Islam MN, Lodh D, Siddiqui MM, Khan AFM, Meherunnesa K. Clinicopathological study on Hypopharyngeal Carcinoma in Dhaka Medical College Hospital. *Bangladesh J otolaryngol* 2015; 21:85-89.
DOI:10.3329/bjo.v21i2.2764
 27. Francis DA, Menon DP. Clinical profile of hypopharyngeal cancer. *Indian journal of Applied Research* 2017; 7:260-61.
 28. Fasunla AJ, Ogundoyin OA, Onakoya PA, Nwaorgu OG. Malignant tumors of the larynx: Clinicopathologic profile and implication for late disease presentation. *Niger Med J* 2016; 57:280-85.
DOI:10.4103/0300-1652.190596.
 29. Jakobsen KK, Wingstrand VL, Jensen JS, Gronhoj C, Jensen DH, Karnov K et al. Incidence and survival of hypopharyngeal cancer: a Danish Nation-Wide Study from 1980 to 2014. *Acta Oncologica* 2019; 58: 1570-76.
DOI:10.1080/0284186X.2019.1657585.