

RESEARCH PAPER

Correlation of Pap Smear and Colposcopy in Relation to Histopathological Findings in Detection of Preinvasive Lesion of Cervix in Bangabandhu Sheikh Mujib Medical University Dhaka, Bangladesh

Noor-E-Ferdous^{1*}, Shirin Akter Begum¹, Mehriban Amatullah², Shereen Yousuf², Tasfia Mahmud³, Latifa Akhter¹, Farzana Sharmin¹, Khairun Nahar², Afroza Khanom⁴

¹Department of Gynecological Oncology, Bangabandhu Sheikh Mujib Medical University (BSMMU), Dhaka, Bangladesh, ²Department of Obstetrics and Gynaecology, Bangabandhu Sheikh Mujib Medical University (BSMMU), Dhaka, Bangladesh, ³Sirajul Islam Medical College, Dhaka, Bangladesh, ⁴Department of Gynaecological Oncology, National Institute of Cancer Research & Hospital (NICRH), Dhaka, Bangladesh.

Abstract

Background: Cervical cancer develops from well-defined precursor lesions in a variable period of time. Detecting in early or pre invasive stages, cervical cancer is preventable and curable, so detection of preinvasive lesions is very important.

Objectives: The aim of our study was to correlate of Pap smear and colposcopy in relation to histopathological findings in detection of preinvasive lesion of cervix.

Methods: This was a cross-sectional study of 110 women to attend in department of Gynecological Oncology OPD of Bangabandhu Sheikh Mujib Medical University from July 2016 to June 2017. Inclusion criteria were age of 30 to 60 years, who had unhealthy cervix, intermenstrual or post coital bleeding and excessive vaginal discharge. Exclusion criteria were any cervical growth, bleeding at the time of examination, pregnant women.

Result: In present study sensitivity of Pap smear for detecting lesions above LSIL was 11(10.0%), specificity 68.38%, PPV was 94.44%, negative predictive value 71.86%. The incidence of preinvasive lesions (LSIL and HSIL) was 33.64% with LSIL 21(19.09%) and HSIL 16(14.55%) and of carcinoma were 10(9.09%).

Conclusion: With a comprehensive approach to make awareness and doing proper screening by Paps smear, colposcopy and colposcopy directed biopsy; cervical cancer can be eliminated as a public health problem within a generation.

Keywords: Pap smear; Colposcopy; Precancerous lesions; Histopathology; HSIL, LSIL.

Introduction

Cervical cancer is a health crisis impacting women and their families across the world specially in low resource setting. In 2020, an estimated 604,237 women were diagnosed with cervical cancer globally, representing 6.5% of all female cancers among in 36 low-and middle -income countries.¹ Cervical cancer killed an estimated 341843 women in 2020, 90% of

whom were in less developed regions of the world, where access to prevention, screening and treatment service are severely limited.¹ In Bangladesh, cervical cancer is the second most common cancer among women, with age-standardized rates (ASRs) for incidence and mortality much higher than the global average statistics (Incidence rates: 19.3 vs. 14.0/100,000 women; Mortality rates: 11.5 vs. 6.8/100,000 women). It is estimated that every year 11,956 new cases of cervical cancer are detected in Bangladesh and 6582 women die of the disease.²

Survival of cervical cancer patients is strongly determined by stage at diagnosis. Due to the late

***Correspondence:** Noor-E-Ferdous, Department of Gynecological Oncology, Bangabandhu Sheikh Mujib Medical University (BSMMU), Dhaka, Bangladesh.

Email: nimmidoel@yahoo.com

ORCID: 0000-0003-1793-0792

stage at diagnosis and inadequate management facilities, mortality rates from cancer cervix are very high in Bangladesh. The overall 5-year relative survival for early and localized cancers is 73.2%, but can be as low as 7.4% for advanced stage disease.³ Cervical cancer is due to the abnormal growth of cell that have the ability to invade or spread to other parts of the body.⁴ Early on typically no symptoms are seen. Later symptoms may include abnormal vaginal bleeding, pelvic pain or pain during sexual intercourse. HPV causes more than 90% of cases.^{4,5} Other risk factors include oral contraceptive pills, early marriage, smoking, weak immune system, multiple sexual partners but these are less important. About 90% of cancer cervix cases are squamous cell carcinoma. 10% are adenocarcinoma. Diagnosis is typically by cervical screening followed by a biopsy.⁵ The most important role of cervical cancer screening tests is to identify the women with high grade squamous intraepithelial lesions (HSIL) because the Low Grade Squamous Intraepithelial Neoplasia (LSIL) are frequently regressive.⁶

It has been well-established that well-organized screening by conventional cytology has substantially reduced the incidence of cervical cancer in developed countries.⁷ Reid Colposcopic Index is a systematic, objective method of colposcopically grading the severity of premalignant cervical lesions. The index considers four colposcopic signs: lesion margin, color of acetowhiteing, blood vessels and iodine staining. Hence use of the index helps direct the clinician to perform a biopsy.⁸ Colposcopy provides a unique method to study the benign and premalignant lesions. It is a simple noninvasive procedure. Pap smear is the lab method while the colposcopy is the clinical method of detection.⁹ Histopathological confirmation is the final gold standard in diagnosis.⁹ Pap smear was interpreted according to the New Bethesda system 2014. Histopathological slides were interpreted according to the WHO classification 2003.¹⁰ Colposcopic grading by Reid Colposcopic index to see the severity of the premalignancy lesions.

As per USPSTF (United State Preventive Services Task Force) recommendation for cervical cancer

screening: woman aged 21 to 65 years are recommended to undergo screening with Papanicolaou smear every 3 years or, for those women 30 to 65 years who want to lengthen their screening interval are recommended to screen with a combination of cytology and HPV testing every 5 years.¹¹

National cervical cancer screening program of Bangladesh was initiated in 2004 as a pilot study and as a national program in 2005.¹² In Bangladesh, the government program of screening test is VIA (Visual Inspection of Cervix by 5% Acetic Acid). Screening test is done in women aged at and above 30 years. There was good compliance for colposcopy but nearly half of patients with high grade precancerous lesion did not receive treatment. Cryotherapy use was infrequent and the policy of “see and treat” was rarely followed. Bangladesh is one of the first countries in the world to introduce VIA as the screening test for its national cervical cancer screening program.¹³

The aim of this study was to find a correlation of Pap smear and colposcopy in detecting the cervical lesions in woman and to analyses the various risk factors.

Materials and Methods

This was a cross sectional study of 110 women who enrolled in the Department of Gynecological Oncology OPD of Bangabandhu Sheikh Mujib Medical University, Dhaka, Bangladesh from July 2016 to June 2017 (one year).

Inclusion criteria

- Women of age between 30-60 years.
- Women with symptoms like chronic leucorrhoea or post-coital bleeding/spotting, intermenstrual bleeding/spotting
- Examination findings of erosion, an unhealthy cervix, a lesion bleeding on touch

Exclusion criteria

- Women with bleeding at the time of examination
- Any cervical growth
- Who underwent treated with precancerous lesions.

Written informed consent was taken after taking proper history and general examination, a per speculum

examination was done in these patients to rule out any gross pathology. In case of leucorrhoea, vaginal smears were done in all cases to rule out infection like candidiasis, trichomonas vaginalis, to detect pseudo mycelia and budding yeast cells and flagellated parasites in trichomonas. Patients were treated for specific and non-specific infection with anti-fungal and anti-protozoal agents. Pap smears were taken in these patients after treating the infections and interpreted as per the Bethesda system of cytological classification. Pap smear was instructed beforehand not to douche the vagina or have sexual intercourse for at least 3 days before the examination. Pap smears were taken from ectocervix and endocervix by Ayres spatula and cytobrush. Smear was made on a glass slide and fixed immediately in a bottle containing 95% absolute alcohol. Every woman included in the study underwent Pap smear and colposcopic examination at the same setting. Colposcopic directed biopsy were taken in all cases. In women with high grade squamous intra epithelial neoplasia (HSIL) will be underwent loop electrosurgical excision procedure (LEEP).

Results

Statistical analysis of the results was obtained by using window-based computer software devised with Statistical Packages for Social Sciences (SPSS-22).

In the present cross-sectional study, a total of 110 cases were enrolled based on the inclusion criteria. 51(46.36%) of cases were in 31-39 years age group followed in order by 30 years 12(10.9%), 40-49 years 31(28.18%) and 50-60 years 16(14.54%). 99(90.0%) of cases were literate (Primary, Secondary, Higher Secondary & above) and 11(10.0%) were illiterate. Majority were 88(80.0%) housewives. Among 55(50.0%) cases were marital age 15-19years. Majority were 40(36.36%) multiparous (Para 3 or more) and 37(33.63%) with para 2 and 18(13.36%) with para 1. (Table I).

Papanicolaou smears were stained and examined and the findings were recorded as NILM (Negative for intraepithelial lesion or malignancy) with 74(67.27%), ASC-US (Atypical squamous cells of undermined significance) with 9(8.18%), LSIL (Low grade squamous intra epithelial lesion) with 11(10.0%), HSIL (High grade squamous intra epithelial lesion) with 7(6.36%) and carcinoma in 3(2.72%) (Figure 1).

Table I: Socio demographic profile

	Age Distribution		p-Value
	n=110	%	
30 years	12	10.90	0.892
31 years to 39 years	51	46.36	
40 years to 49 years	31	28.18	
50 years to 60 years	16	14.54	
Mean±SD	2.46±0.892		
Educational status			
Illiterate	11	10.00	0.063
Primary	31	28.18	
Secondary	42	38.18	
Higher Secondary & above	26	23.64	
Mean±SD	2.82±0.934		
Occupation			
Housewife	88	80.00	0.015
Service	17	15.47	
Business	0	0.0	
Teacher	4	3.34	
Physician	1	0.92	
Mean±SD	1.29±0.724		
Marital age			
<10	9	8.18	0.079
15-19	55	50.0	
20-29	39	35.45	
>29	7	6.36	
Mean±SD	2.38±0.736		
Parity			
1	18	16.36	0.009
2	37	33.63	
3	40	36.36	
>3	12	10.91	
Nil	3	2.74	
Mean+SD	2.40+0.965		

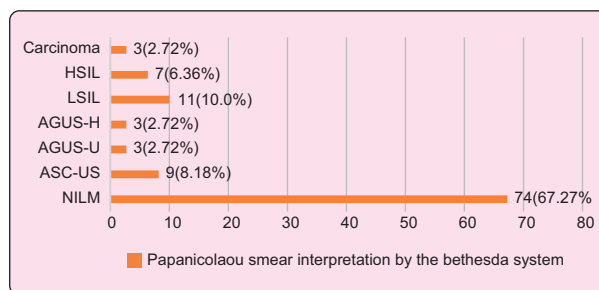


Figure 1: Distribution of various grade of Cytology (pap smear)

White discharge was the most common clinical symptom 61(55.45%) among the cases and others were post coital bleeding 15(13.64%), pain in abdomen 10(9.09%) low backache 19(17.27%),

postmenopausal bleeding 15(13.64%) and menstrual disorders 12(10.91%) (Figure 2).

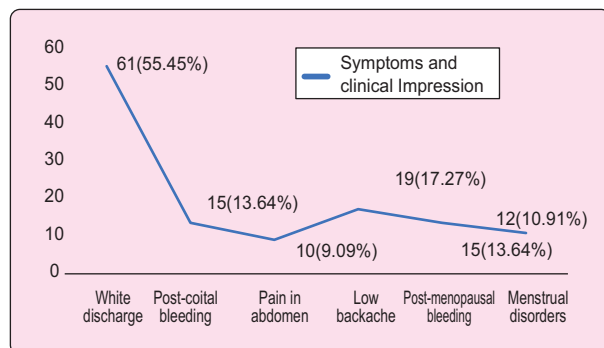


Figure 2: Symptoms and clinical Impression

Table II summarizes the findings of histopathological findings among the cases in the study with 63(57.27%) with chronic cervicitis with metaplasia, 21(19.09%) LSIL, 16(14.55%) HSIL and 10(9.09%) Carcinomas.

Table II: Distribution of various grade of Histopathology

Histopathological Findings	n=110	%
Chronic cervicitis	63	57.27
LSIL (Mild Dysplasia)	21	19.09
HSIL (Moderate to severe)	16	14.55
Carcinoma	10	9.09

In the present study, the sensitivity of colposcopy in detection of low-grade lesions and above came out to be 65.38%, specificity 95.83%, positive predictive value 94.44%, negative predictive value 71.86% and accuracy of colposcopy in our study was 80.00%.

Table III: Sensitivity and Specificity of PAP smear

Sensitivity	TP/TP+FN	65.38
Specificity	TN/TN+FP	95.83
PPV	TP/TP+FP	94.44
NPV	TN/TN+FN	71.86
Accuracy	TP+TN/TP+TN+FP+FN	80.00

Table V: Correlation between pap smear report and histopathological report

Pap Smear	Histopathological report				Total
	Chronic cervicitis	LSIL (Mild Dysplasia)	HSIL (Moderate to severe)	Carcinoma	
NILM	55(50.0%)	11(10.0%)	5(4.55%)	3(2.72%)	74
ASC (US)	2(1.82%)	7(6.36%)	3(2.72%)	3(2.72%)	15
LSIL	5(4.55%)	3(2.72%)	2(1.82%)	1(0.91%)	11
HSIL	1(0.91%)	-	4(3.64%)	1(0.91%)	6
Carcinoma	-	1(0.91%)	1(0.91%)	2(1.82%)	4
Total	63	22	15	10	110

NILM: Negative for Intraepithelial Lesion or Malignancy; ASC (US): Atypical Squamous Cells of Undetermined Significance; LSIL: Low-grade squamous intraepithelial lesion; HSIL: high-grade intraepithelial lesion

All the cases were examined by colposcopy and graded as per Reid colposcopic score as, benign inflammatory (Score 0-2), low grade (score 3-5), high grade (Score 6-8) and if >8 considered as carcinoma. Based on the scoring system, majority were benign inflammatory 65(59.09%), low grade 26(23.64%), high grade 15(13.64%) and 4(3.63%) as carcinoma (Table V).

Table IV: Distribution of Colposcopy

Reid colposcopy score	n=110	%
0-2 (Benign inflammatory)	65	59.09
3-5 (Low Grade)	26	23.64
6-8 (High Grade)	15	13.64
>8 (Carcinoma)	4	3.63
Total	110	100.0

Table V summarizes the correlation between Pap smear and histopathological finding in our study. Table VI describes the correlation between colposcopic findings and histopathological findings of our study. The findings of histopathological findings among the cases in the study with 63(57.27%) with chronic cervicitis with metaplasia, 21(19.09%) LSIL, 16(14.55%) HSIL and 10(9.09%) carcinomas.

Table VI describes the correlation between colposcopic findings and histopathological findings of our study. In the present study, the sensitivity of colposcopy in detection of low-grade lesions and above came out to be 80.2%, specificity 82.14%, positive predictive value 66.78%, negative predictive value 86.78% and accuracy of colposcopy in our study was 84.65%. The incidence of preinvasive lesions (LSIL and HSIL) was 33.6% with LSIL (19.2%) and HSIL (14.4%). The incidence of invasive lesions in our study was 9.6% (24/250).

Table VI: Correlation between colposcopy findings and histopathological report

Colposcopy	Histopathological report				Total
	Chronic cervicitis	LSIL (Mild Dysplasia)	HSIL (Moderate to severe)	Carcinoma	
0-2 (Benign Inflammatory)	53(48.18%)	7(6.36%)	5(4.55%)	0	65
3-5 (Low grade)	8(7.27%)	11(10.0%)	5(4.55%)	2(1.82%)	26
6-8 (high grade)	1(0.91%)	4(3.64%)	6(5.45%)	4(3.63%)	15
>8 Carcinoma	-	-	-	4(3.63%)	4
Total	62	22	16	10	110

Discussion

In the present study, 31-39 years age group was the most common group and this indicates that premalignant lesions (dysplasia) precede the development of malignancy by a decade and prompt identification by appropriate screening reduces the mortality and morbidity associated with cervical cancer. Parity 3 women were more common in our study (36.36%) indicating that women with early sexual exposure in early life and more children are associated with more chance of abnormal findings in screening for cervical premalignant lesions. The mean parity of women in our study was 3 which is similar to findings of Goel et al.¹⁴

In this study, Mean+SD parity of the patients was 2.40+0.965 and 40(36.36%) were parity 3 and 37 (33.63%) were parity 2. Almost similar distribution of parity 3 (98.10%) and parity 2 (43.2%) were seen in a study in BSMMU, Bangladesh Ferdous J et al, 2013.¹⁵

In the present study by colposcopic Reid index and graded as, benign inflammatory (Score 0-2), low grade (score 3-5), high grade (Score 6-8) and if >8 considered as carcinoma. Based on the scoring system, majority were benign inflammatory 65(59.09%), low grade 26(23.64%), high grade 15(13.64%) and 4(3.63%) as carcinoma which is correlated with this study.¹⁶

Colposcopy directed biopsy proved to be a superior screening test to detect epithelial cell abnormality due to its higher sensitivity and positive predictive value which was reported by Vassilkos et al. (2000).¹⁷ There is a strong correlation between findings of Pap smear, Colposcopy and colposcopy directed histopathology report. Therefore, these tests are all together are useful and complementary in arriving at a correct diagnosis.

In this study, the sensitivity of colposcopy was 65.38% for cervical cancer screening which was more than conventional pap's smear (3.8%). Colposcopy

cytology increases the detection rate of low grade squamous intraepithelial lesion and high grade squamous intraepithelial lesion by 47 and 116% respectively compared with conventional pap smear test which is correlated with this study.¹⁸

In Histopathological examination, majority of the cases in our study was chronic cervicitis 55% followed by mild dysplasia (19.2%), moderate to severe in 14.4% and 9.6% malignant lesions. Findings of our study coincide with the reports of Bodal and Brar who reported malignancy in 8.5% of cases in his study.¹⁹

It also helps in determining the site of biopsy, patients for conservative treatment of CIN, follow up of intraepithelial neoplasia and invasive lesions. On Pap smear, majority of the cases reported were NILM (67.2%), and frank malignancy was reported in 3.2% of cases and LSIL and HSIL in 9.6% and 6.4%. Findings of our study coincide with the findings of Bal MS et al.²⁰ However findings in the study of Shastri SS et al, 95.4% were normal, 0.026% had LSIL, 0.01% has HSIL and 0.007% had invasive carcinoma.²¹ These differences in Pap smear reporting's are due to differences in sampling, staining, fixation techniques and reporting errors.

Hence the present study strongly suggests that colposcopy and colposcopic directed biopsy of cervix should be included along with the Pap smear in screening for early detection of cervical cancer and usage increases the accuracy of detection of cervical abnormalities is higher when used complementarily.

Limitation of the Study

This was a cross-sectional study with a small sized sample. So, the findings of this study may not reflect the exact scenario of the whole country.

Conclusion

The women of 30 to 50 years should get the highest priority in the screening programme in Bangladesh.

The Government of Bangladesh should provide more efforts to implement marriage law and provide high quality family planning service for limiting childbirth. Screening program helps in early detection of cervical cancer and the program expansion and gradual improvement of population coverage is very important to prevent advanced stage disease.

Recommendation

This study can serve as a pilot to a much larger research involving multiple centers that can provide a nationwide picture, validate regression models proposed in this study for future use and emphasize points to ensure better management and adherence.

Conflict of Interest: There was no conflict of interest.

Funding: None.

Ethical approval: IRB of Bangabandhu Sheikh Mujib Medical University, Dhaka, Bangladesh.

Submitted: 26 September 2021

Final revision received: 23 May 2022

Accepted: 29 May 2022

Published: 01 December 2022

References

1. WHO: Women and cervical and breast cancer – WHO Available from: [https://www.who.int/home/cms-commissioning]
2. Jadranka R. Squamous Intra-epithelial lesion. Arch Oncol. 2001;9(3):165-70. Available: <http://www.onk.ns.ac.rs/archive/Vol9/PDFVol9/V9n3p165.pdf>
3. Ahmedin J, Siegel R, Elizabeth W, Taylor M, Jiaquan X, Carol S. Cancer statistics. Cancer J Clin. 2006;56:106-30. DOI: 10.3322/canjclin.56.2.106
4. Algotar K, Nalawade A, Sachdev S. Predictive value of colposcopy in cervical cancer screening. Bombay Hospital J. 2004;4603.
5. Berek JS. Cervical and vaginal cancer. Berek and Novaks gynecology, 15th Ed. New York, NY: Lippincott Williams and Wilkins; 2012:2262-64.
6. Arora R, Vijaya K, Habeebullah S, Oumachigui A. Colposcopic evaluation of unhealthy cervix. J ObstetGynaecol India. 2000;50:102-3. Available from: https://jogi.co.in/articles/files/filebase/Archives/2000/dec/2000_102_103_Dec.pdf
7. Patil S, Patil A, Solanke P. Cytological Screening for early Diagnosis of Cervical Intraepithelial Neoplasia (CIN) and early Carcinoma of Cervix. International Journal of Scientific and Research Publications. 2015.
8. Ferris DG, Greenberg MD. Reid's colposcopic index. Journal of family practice. 1994 Jul 1;39:65-70. PMID: 7517993
9. Lawley TB, Lee RB, Kapela RR. The significance of moderate and severe inflammation on class I Papanicolaou smear. Obstet Gynecol. 1990;76:997. PMID: 2234731
10. Eble JN, Tavassoli FA, Devilee P, editors. Pathology and genetics of tumours of the breast and female genital organs. Iarc; 2003.
11. Handa PR, Dhall GI. Colposcopy as diagnostic aid in cases of suspicious cervix. J ObstetGynaecol India. 1991;41:785-92.
12. Jones HW. Cervical cancer precursors and their management. Telindes operative gynecology. 9th edition; 2015:1354-60.
13. Ferlay J, Shin HR, Bray F, Forman D, Mathers C, Parkin DM; Estimates of worldwide burden of cancer in 2008: GLOBOCAN 2008. Int J Cancer, 2010; 127:2893-917.
14. Goel A, Gandhi G, Batra S, Bhambani S, Zutshi V, Sachdeva P. Visual inspection of the cervix with acetic acid for cervical Intraepithelial lesions. Dept of Obstetrics and Gynaecology, MaulanAzad medical college, new Delhi, India. Int J Gynecol Obstet. 2005;88:25-30.
15. Ferdous J, Begum SA, Nahar Q, Khatun SF, Khatun S. Presentation of invasive cervical cancer in Bangladesh. Bangabandhu Sheikh Mujib Medical University Journal. 2013;6:29-32.
16. Gandavaram J, Pamulapati BR. Correlation of Pap smear and colposcopic findings in relation to histopathological findings among women attending a tertiary care hospital: a two year study. International Journal of Reproduction, Contraception, Obstetrics and Gynecology. 2019;8:2164.
17. Vassilikos EJ, Yu H, Trachtenberg J, Nam RK, Narod SA, Bromberg IL, Diamandis EP. Relapse and cure rates of prostate cancer patients after radical prostatectomy and 5 years of follow-up. Clinical biochemistry. 2000 Mar 1;33:115-23.
18. Khatun S, Khatun SF. Conventional pap's test and liquid-based cytology for the screening of cervical cancer with back up colposcopy directed biopsy. Bangabandhu Sheikh Mujib Medical University Journal. 2019 Jul 2;12:105-8.
19. Bodal VK, Brar BK. Correlation of pap smear with histopathological findings in malignant and nonmalignant lesions of cervix. Glob J Med Res E Gynecol Obstet. 2014;14:19-23.
20. Bal MS, Goyal R, Suri AK, Mohi MK. Detection of abnormal cervical cytology in Papanicolaou smears. J Cytol. 2012;29:45-7.
21. Shastri SS, Dinshaw K, Amin G, Goswami S, Patil S, Chinoy R, et al. Concurrent evaluation of Visual cytological and HPV testing as screening methods for the early detection of cervical neoplasia in Mumbai, India. Bull World Healthy Organ. 2005;83:186-94.